



DISTAL RADIAL FRACTURE CASE 2

Articular displaced distal radius fracture treated with VRP PEEK plate

AT A GLANCE

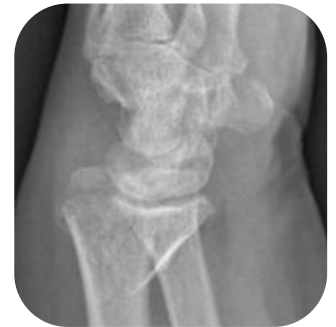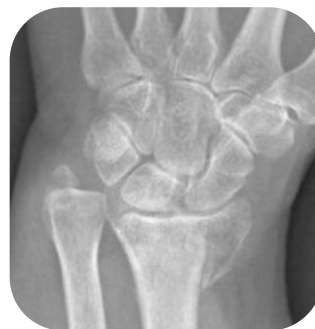PATIENT DETAILS

- 73 yr old female
- Left wrist, low energy trauma at home
- Patient has heart disease and osteoporosis, no other fractures

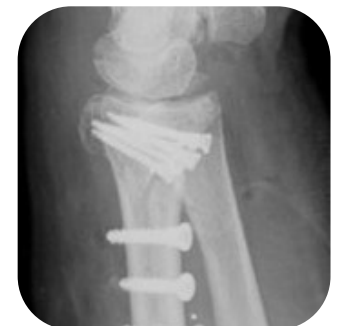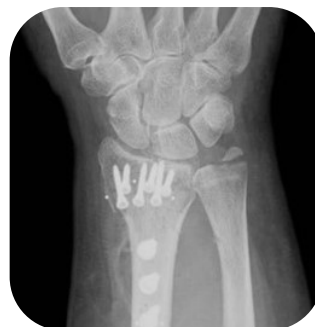POST OP REGIME

- After the surgery, the patient was immobilised in forearm splint for 1 week and then started physiotherapy to reach the best functional result possible

PRE OP



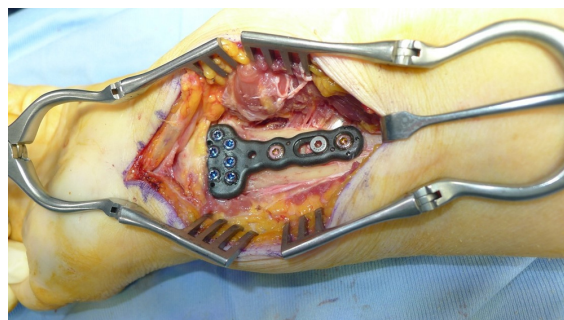
POST OP



Discussion

3 months after the surgery there was a deficit of 10° in flexion and 5° in extension. She was able to come back to all her normal activities. No major complications were identified.

INTR OP



Surgeon

Prof Tarallo is an orthopaedic surgeon who trained at the university of Modena and Reggio Emilia specializing in orthopaedics and traumatology with a particular interest in upper extremity diseases.